

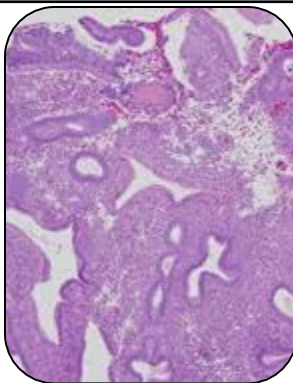
<b>Patient Name</b>	MRS. DOLLY	<b>Client Name</b>	Advanta Super Speciality Hospital (Rohtak)	<b>Specimen Received</b>	12/01/2017
<b>Age/Sex</b>	24/F	<b>Client Code</b>	MOLQ1299CM	<b>Specimen Type</b>	Tissue
<b>Patient ID</b>	011701120154	<b>Ref. Doctor</b>		<b>Collection Date</b>	12/01/2017
<b>Specimen ID</b>	MOLQ/B-24/17			<b>Report Date</b>	15/01/2017

## SURGICAL PATHOLOGY REPORT

### Proliferative phase, Endometrial curettings.

#### DIAGNOSIS

**PROLIFERATIVE PHASE.**



#### SPECIMEN

Endometrial curettings.

#### GROSS

- i) Received multiple greyish white tissue pieces.

#### Microscopy

- 1) Section examined shows Paucicellular small broken endometrial glands having cuboidal epithelial cells with small round nucleus.
- 2) Stroma shows large number of RBC and inflammatory cells.
- 3) No granuloma and no malignant cells seen.

**Note :** All biopsy specimen will be stored for 15 (fifteen)days, block and slides for 5(five) years only from the time of receipt at the laboratory. No request ,for any of the above ,will be entertained after the due date.

#### Reference

- i) Rosai and Ackerman's Surgical Pathology.
- ii) Modern Surgical Pathology.

A handwritten signature in black ink, appearing to read 'Gulshan', written over a white rectangular background.

**Gulshan Yadav, MD**  
**Consultant Pathologist**