

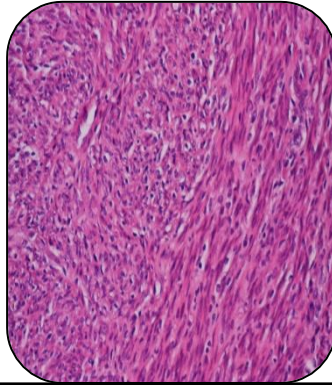
<b>Patient Name</b>	Mrs. PARVEEN KUMARI	<b>Client Name</b>	Satyam Hospital, MadanPuri	<b>Specimen Received</b>	06/01/2017
<b>Age/Sex</b>	35/F			<b>Specimen Type</b>	Tissue
<b>Patient ID</b>	011701060089	<b>Client Code</b>	MOLQ1413CM	<b>Collection Date</b>	06/01/2017
<b>Specimen ID</b>	MOLQ/B-15/17	<b>Ref. Doctor</b>		<b>Report Date</b>	10/01/2017

## SURGICAL PATHOLOGY REPORT

**Fallopian tube confirmed and unremarkable, Left fallopian tube.**

### DIAGNOSIS

**FALLOPIAN TUBE CONFIRMED AND UNREMARKABLE.**



### SPECIMEN

Left fallopian tube.

### GROSS

i) Received 0.5x1cm greyish white tissue piece.

### Microscopy

1) Section examined shows lining epithelium having cuboidal cells with oval nucleus.

**Note :** All biopsy specimen will be stored for 15 (fifteen)days, block and slides for 5(five) years only from the time of receipt at the laboratory. No request ,for any of the above ,will be entertained after the due date.

### Reference

- i) Rosai and Ackerman's Surgical Pathology.
- ii) Modern Surgical Pathology.

**Gulshan Yadav, MD**  
**Consultant Pathologist**

*Report generated at MolQ Laboratory, Gurgaon*