

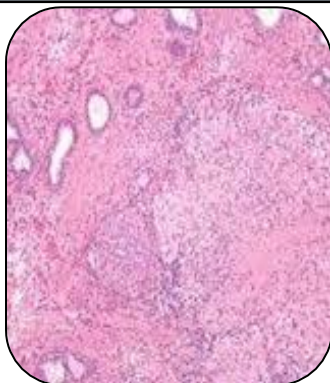
<b>Patient Name</b>	MR. NARESH	<b>Client Name</b>	Multispeciality Hospital- Gurgaon	<b>Specimen Received</b>	24/12/2016
<b>Age/Sex</b>	32/M	<b>Client Code</b>	MOLQ1269P	<b>Specimen Type</b>	Tissue
<b>Patient ID</b>	011612240017	<b>Ref. Doctor</b>		<b>Collection Date</b>	24/12/2016
<b>Specimen ID</b>	MOLQ/B-848/16			<b>Report Date</b>	08/01/2017

## SURGICAL PATHOLOGY REPORT

### Non specific inflammation, Fistula.

#### DIAGNOSIS

**NON SPECIFIC INFLAMMATION.**



#### SPECIMEN

Fistula.

#### GROSS

i) Received 5x2cm greyish white tissue piece with skin with fistula tract.

#### Microscopy

- 1) Section examined shows ulcerated squamous lining epithelial having small round to oval nucleus.
- 2) Deeper tissue shows fibrocollagenous tissue and mononuclear inflammatory cells.

**Note :** All biopsy specimen will be stored for 15 (fifteen)days, block and slides for 5(five) years only from the time of receipt at the laboratory. No request ,for any of the above ,will be entertained after the due date.

#### Reference

- i) Rosai and Ackerman's Surgical Pathology.
- ii) Modern Surgical Pathology.

A handwritten signature in black ink, appearing to read 'Gulshan', written over a white rectangular background.

**Gulshan Yadav, MD**  
**Consultant Pathologist**