

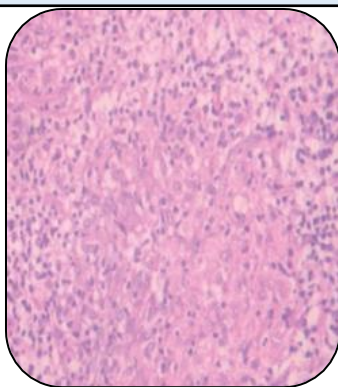
<b>Patient Name</b>	MOHD. SHAHID	<b>Client Name</b>	Ghosh Path Lab	<b>Specimen Received</b>	23/12/2016
<b>Age/Sex</b>	42/M	<b>Client Code</b>	MOLQ1123CM	<b>Specimen Type</b>	Tissue
<b>Patient ID</b>	011612230096	<b>Ref. Doctor</b>	DR. GHOSH	<b>Collection Date</b>	23/12/2016
<b>Specimen ID</b>	MOLQ/B-846/16			<b>Report Date</b>	02/01/2017

## SURGICAL PATHOLOGY REPORT

### Non specific inflammation, Biopsy large bowel .

#### DIAGNOSIS

**NON SPECIFIC INFLAMMATION.**



#### SPECIMEN

Biopsy large bowel .

#### GROSS

i) Received very tiny greyish white tissue pieces.

#### Microscopy

- 1) Section examined shows mucosal lining epithelium with columnar cells and oval shaped nucleus.
- 2) Section also shows mild atrophy of villi.
- 3) Sub mucosa shows sub mucosal glands with mononuclear inflammatory cells.
- 4) No granuloma and no malignant cell seen in specimen received.

**Note :** All biopsy specimen will be stored for 15 (fifteen)days, block and slides for 5(five) years only from the time of receipt at the laboratory. No request ,for any of the above ,will be entertained after the due date.

#### Reference

- i) Rosai and Ackerman's Surgical Pathology.
- ii) Modern Surgical Pathology.

**Gulshan Yadav, MD**  
Consultant Pathologist