

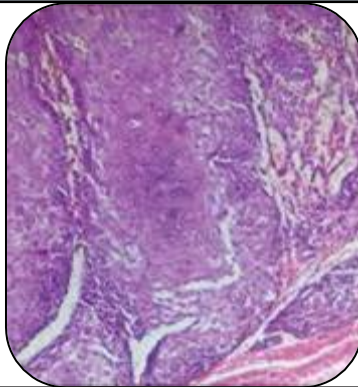
Patient Name	Mr. NARESH KUMAR	Client Name	Ghosh Path Lab	Specimen Received	13/12/2016
Age/Sex	60/M	Client Code	MOLQ1123CM	Specimen Type	Tissue
Patient ID	011612130055	Ref. Doctor		Collection Date	13/12/2016
Specimen ID	MOLQ/B-817/16			Report Date	22/12/2016

SURGICAL PATHOLOGY REPORT

Mole on Face.

DIAGNOSIS

BENIGN HYPERKERATOTIC LESION (MOLE).



SPECIMEN

Mole on Face.

GROSS

i) Received 1x1cm greyish white tissue piece.

Microscopy

- 1) Section examined shows Squamous lining epithelium having small round nucleus with hyperkeratosis and Para keratosis.
- 2) Dermis shows fibrocollagenous tissue and mononuclear inflammatory cells.

Note : All biopsy specimen will be stored for 15 (fifteen)days, block and slides for 5(five) years only from the time of receipt at the laboratory. No request ,for any of the above ,will be entertained after the due date.

Reference

- i) Rosai and Ackerman's Surgical Pathology.
- ii) Modern Surgical Pathology.

Gulshan Yadav, MD
Consultant Pathologist