

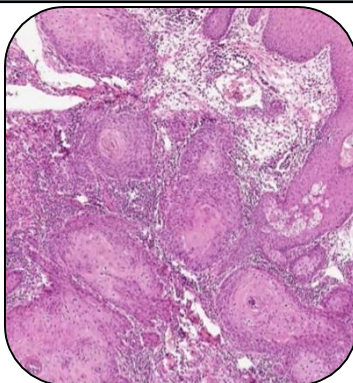
Patient Name	Mast. OM BALIYAN	Client Name	MolQ Collection Centre- V, Ambala	Specimen Received	17/12/2016
Age/Sex	04/M	Client Code	MOLQ1207A	Specimen Type	Tissue
Patient ID	011612170143	Ref. Doctor	CHD LAB	Collection Date	17/12/2016
Specimen ID	MOLQ/B-823/16			Report Date	21/12/2016

SURGICAL PATHOLOGY REPORT

Dermoid Cyst, Cyst.

DIAGNOSIS

DERMOID CYST.



SPECIMEN

Cyst.

GROSS

i) Received 2.5x0.5cm greyish white tissue pieces.

Microscopy

- 1) Section examined shows Squamous lining epithelium with small round nucleus.
- 2) Deeper tissue shows fibrocollagenous tissue, blood vessels, cartilage, muscle bundles.
- 3) No granuloma and no malignant seen.

Note : All biopsy specimen will be stored for 15 (fifteen)days, block and slides for 5(five) years only from the time of receipt at the laboratory. No request ,for any of the above ,will be entertained after the due date.

Reference

- i) Rosai and Ackerman's Surgical Pathology.
- ii) Modern Surgical Pathology.

Gulshan Yadav, MD
Consultant Pathologist