

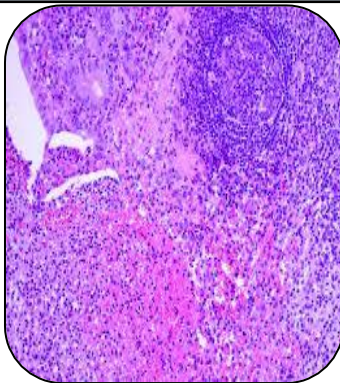
<b>Patient Name</b>	MR. SACHIN	<b>Client Name</b>	Kriti Hospital	<b>Specimen Received</b>	12/12/2016
<b>Age/Sex</b>	18/M	<b>Client Code</b>	MOLQ1112CM	<b>Specimen Type</b>	Tissue
<b>Patient ID</b>	011612120148	<b>Ref. Doctor</b>		<b>Collection Date</b>	12/12/2016
<b>Specimen ID</b>	MOLQ/B-811/16			<b>Report Date</b>	17/12/2016

## SURGICAL PATHOLOGY REPORT

### Acute Appendicitis, Appendix.

#### DIAGNOSIS

**ACUTE APPENDICITIS.**



#### SPECIMEN

Appendix.

#### GROSS

- i) Received 6x1cm long appendix.
- ii) Cut section shows fecolith.

#### Microscopy

- i) Section examined shows lymphoid follicles with ulcerated mucosa.
- ii) Deeper tissue shows inflammatory infiltrate.

**Note :** All biopsy specimen will be stored for 15 (fifteen) days, block and slides for 5 (five) years only from the time of receipt at the laboratory. No request, for any of the above, will be entertained after the due date.

#### Reference

- i) Rosai and Ackerman's Surgical Pathology.
- ii) Modern Surgical Pathology.

**Gulshan Yadav, MD**  
Consultant Pathologist