

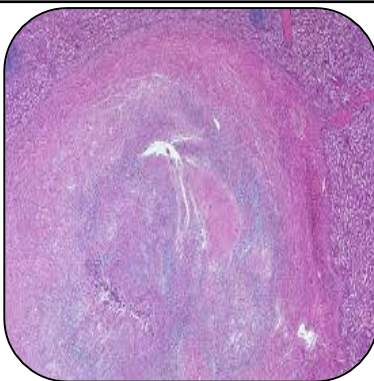
<b>Patient Name</b>	MR. LOVE JINDAL	<b>Client Name</b>	Global Pathology	<b>Specimen Received</b>	11/12/2016
<b>Age/Sex</b>	12/M		Centre	<b>Specimen Type</b>	Tissue
<b>Patient ID</b>	011612110021	<b>Client Code</b>	MOLQ1283CM	<b>Collection Date</b>	11/12/2016
<b>Specimen ID</b>	MOLQ/B-805/16	<b>Ref. Doctor</b>	Self	<b>Report Date</b>	17/12/2016

## SURGICAL PATHOLOGY REPORT

### Acute Appendicitis, Appendix.

#### DIAGNOSIS

**ACUTE APPENDICITIS.**



#### SPECIMEN

Appendix.

#### GROSS

Received 5x1.5cm long appendix. Cut section shows fecolith.

#### Microscopy

- i) Section examined shows lymphoid follicles with ulcerated mucosa.
- ii) Deeper tissue shows inflammatory infiltrate.

#### Reference

- i) Rosai and Ackerman's Surgical Pathology.
- ii) Modern Surgical Pathology.

**Gulshan Yadav, MD**  
Consultant Pathologist