

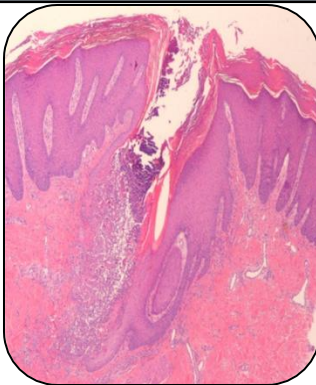
Patient Name	MRS. PARBHA	Client Name	Advanta Super Speciality Hospital (Rohtak)	Specimen Received	09/12/2016
Age/Sex	48/F	Client Code	MOLQ1299CM	Specimen Type	Tissue
Patient ID	011612090171	Ref. Doctor		Collection Date	09/12/2016
Specimen ID	MOLQ/B-804/16			Report Date	17/12/2016

SURGICAL PATHOLOGY REPORT

Benign Hyperkeratotic lesion, Dermoid cyst scalp.

DIAGNOSIS

BENIGN HYPERKERATOTIC LESION.



SPECIMEN

Dermoid cyst scalp.

GROSS

i) Received 1x1cm greyish white tissue piece with skin.

Microscopy

- 1) Section examined shows Squamous lining epithelium with small round to oval nucleus with hyperkeratosis.
- 2) No granuloma and no malignant seen.

Note : All biopsy specimen will be stored for 15 (fifteen)days, block and slides for 5(five) years only from the time of receipt at the laboratory. No request ,for any of the above ,will be entertained after the due date.

Reference

- i) Rosai and Ackerman's Surgical Pathology.
- ii) Modern Surgical Pathology.

A handwritten signature in black ink, appearing to read 'Gulshan', written over a white rectangular background.

Gulshan Yadav, MD
Consultant Pathologist