

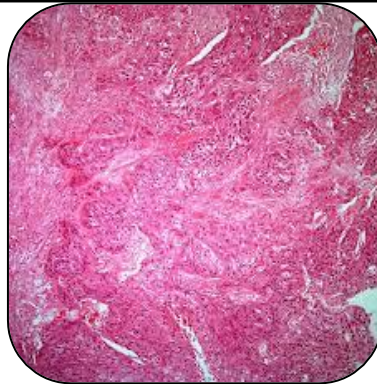
<b>Patient Name</b>	MR. JITENDER GOYAL	<b>Client Name</b>	Patient Care Centre	<b>Specimen Received</b>	10/12/2016
<b>Age/Sex</b>	45/M			<b>Specimen Type</b>	TISSUE
<b>Patient ID</b>	011612100076	<b>Client Code</b>	MOLQ1249C	<b>Collection Date</b>	10/12/2016
<b>Specimen ID</b>	MOLQ/B-803/16	<b>Ref. Doctor</b>	DR. VIVEK BHATIA	<b>Report Date</b>	14/12/2016

## SURGICAL PATHOLOGY REPORT

### Non specific inflammation, Duodenal ulcer Biopsy.

#### DIAGNOSIS

**NON SPECIFIC INFLAMMATION.**



#### SPECIMEN

Duodenal ulcer Biopsy.

#### GROSS

Received 0.5x0.5cm greyish white tissue piece.

#### Microscopy

- 1) Section examined shows mucosal lining epithelium and villa having small round nucleus.
- 2) Sub mucosa shows mononuclear inflammatory cells , plasma cells and sub mucosal glands.
- 3) Mucosa also shows metaplasia.
- 4) No granuloma , no crypt abscess and no malignant cells seen

#### Reference

- i) Rosai and Ackerman's Surgical Pathology.
- ii) Modern Surgical Pathology.

A handwritten signature in black ink, likely belonging to the pathologist who reviewed the specimen.