

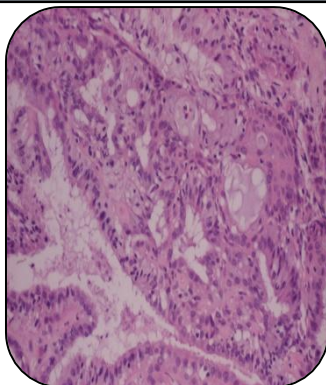
Patient Name	MRS. PARTIMA	Client Name	Advanta Super Speciality Hospital (Rohtak)	Specimen Received	05/12/2016
Age/Sex	23/F	Client Code	MOLQ1299CM	Specimen Type	Tissue
Patient ID	011612050149	Ref. Doctor		Collection Date	05/12/2016
Specimen ID	MOLQ/B-796A/16			Report Date	10/12/2016

SURGICAL PATHOLOGY REPORT

Right Fallopian Tube.

DIAGNOSIS

FALLOPIAN TUBE CONFIRMED AND UNREMARKABLE.



SPECIMEN

Right Fallopian Tube.

GROSS

- i) Received 1x1cm greyish white tissue piece.

Microscopy

- 1) Section examined shows small endometrial glands having cuboidal epithelium with small round nucleus with cystically dilated glands.
- 2) Stroma shows mononuclear inflammatory cells.
- 3) No atypical cell seen.

Note : All biopsy specimen will be stored for 15 (fifteen)days, block and slides for 5(five) years only from the time of receipt at the laboratory. No request ,for any of the above ,will be entertained after the due date.

Reference

- i) Rosai and Ackerman's Surgical Pathology.
- ii) Modern Surgical Pathology.

Gulshan Yadav, MD
Consultant Pathologist