

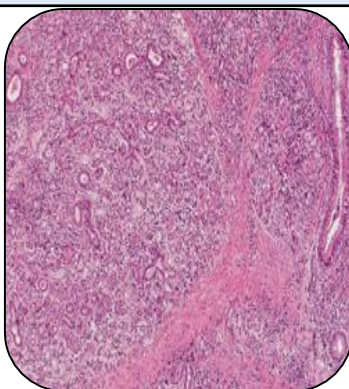
<b>Patient Name</b>	MRS. MEENA DEVI	<b>Client Name</b>	Kriti Hospital	<b>Specimen Received</b>	02/12/2016
<b>Age/Sex</b>	45/F	<b>Client Code</b>	MOLQ1112CM	<b>Specimen Type</b>	Tissue
<b>Patient ID</b>	011612020013	<b>Ref. Doctor</b>		<b>Collection Date</b>	02/12/2016
<b>Specimen ID</b>	MOLQ/B-789/16			<b>Report Date</b>	10/12/2016

## SURGICAL PATHOLOGY REPORT

### Chronic Cervicitis with Endometrium Polyp, Uterus with Cervix.

#### DIAGNOSIS

**CHRONIC CERVICITIS WITH ENDOMETRIUM POLYP.**



#### SPECIMEN

Uterus with Cervix.

#### GROSS

- i) Received 10x4.5cm uterus with cervix.
- ii) Cut section shows endometrium polyp 1x2cm.

#### Microscopy

- i) Section examined shows small endometrial glands in proliferative phase.
- ii) Myometrium shows muscle bundles. Cervix shows mononuclear inflammatory cells.
- iii) Polyp shows small endometrial glands.

**Note :** All biopsy specimen will be stored for 15 (fifteen) days, block and slides for 5 (five) years only from the time of receipt at the laboratory. No request, for any of the above, will be entertained after the due date.

#### Reference

- i) Rosai and Ackerman's Surgical Pathology.
- ii) Modern Surgical Pathology.

**Gulshan Yadav, MD**  
Consultant Pathologist