

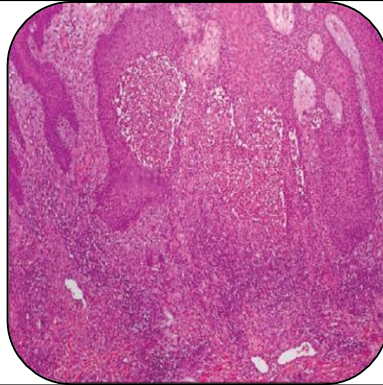
<b>Patient Name</b>	MRS. JOSHU SRIVASTAVA	<b>Client Name</b>	Dhanwantri X-Ray Lab	<b>Specimen Received</b>	03/12/2016
<b>Age/Sex</b>	51/F			<b>Specimen Type</b>	Tissue
<b>Patient ID</b>	0 11612030094	<b>Client Code</b>	MOLQ1193CW	<b>Collection Date</b>	03/12/2016
<b>Specimen ID</b>	MOLQ/B-792/16	<b>Ref. Doctor</b>	MANJU SRIVASTAVA	<b>Report Date</b>	10/12/2016

## SURGICAL PATHOLOGY REPORT

### Hyperkeratotic lesion (WART), Wart.

#### DIAGNOSIS

**HYPERKERATOTIC LESION (WART).**



#### SPECIMEN

Wart.

#### GROSS

i) Received Very tiny tissue pieces 0.5x0.5cm.

#### Microscopy

- 1) Section examined shows Squamous lining epithelium having small round nucleus and keratin.
- 2) No malignant cells seen in section prepared.

#### Reference

- i) Rosai and Ackerman's Surgical Pathology.
- ii) Modern Surgical Pathology.

A handwritten signature in black ink, appearing to read 'Gulshan', written over a white rectangular background.

**Gulshan Yadav, MD**  
**Consultant Pathologist**