

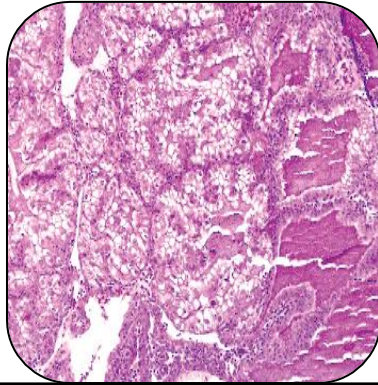
Patient Name	MRS. PARMINDER	Client Name	Gumti Diagnostics	Specimen Received	02/12/2016
Age/Sex	45/F	Client Code	MOLQ1208A	Specimen Type	Tissue
Patient ID	011612020050	Ref. Doctor	JAIN NURSING HOME	Collection Date	02/12/2016
Specimen ID	MOLQ/B-791/16			Report Date	10/12/2016

SURGICAL PATHOLOGY REPORT

Decidual reaction(Hyperprogestronic Effect), Thicker Endometrium.

DIAGNOSIS

Decidual Reaction(Hyperprogestronic Effect).



SPECIMEN

Thicker Endometrium.

GROSS

i) Received multiple greyish white tissue pieces.

Microscopy

- 1) Section examined shows decidual cells having small round nucleus with mononuclear inflammatory cells.
- 2) No endometrium glands seen in sample received.
- 3) No granuloma seen.

Note : All biopsy specimen will be stored for 15 (fifteen)days, block and slides for 5(five) years only from the time of receipt at the laboratory. No request ,for any of the above ,will be entertained after the due date.

Reference

- i) Rosai and Ackerman's Surgical Pathology.
- ii) Modern Surgical Pathology.

Gulshan Yadav, MD
Consultant Pathologist

Report generated at MolQ Laboratory, Gurgaon