

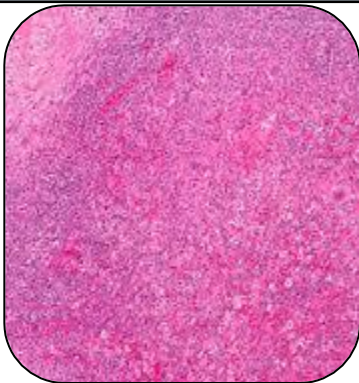
Patient Name	Mr. KANTA PRASAD GUPTA	Client Name	Ghosh Path Lab	Specimen Received	25/11/2016
Age/Sex	83/M	Client Code	MOLQ1123CM	Specimen Type	Tissue
Patient ID	011611250068	Ref. Doctor		Collection Date	25/11/2016
Specimen ID	MOLQ/B-777/16			Report Date	03/12/2016

SURGICAL PATHOLOGY REPORT

Benign Prostatic Hyperplasia with Prostatitis, T.U.R.P.

DIAGNOSIS

BENIGN PROSTATIC HYPERPLASIA WITH PROSTATITIS.



SPECIMEN

T.U.R.P.

GROSS

i) Received multiple grayish white tissue pieces measuring 3x2.5cm aggregate.

Microscopy

1) Section examined shows large number of prostatic glands having bilayer epithelium with small round nucleus and surrounded by large number of fibrocollagenous tissue with mononuclear inflammatory cells.

Note : All biopsy specimen will be stored for 15 (fifteen)days, block and slides for 5(five) years only from the time of receipt at the laboratory. No request ,for any of the above ,will be entertained after the due date.

Reference

- i) Rosai and Ackerman's Surgical Pathology.
- ii) Modern Surgical Pathology.

Gulshan Yadav, MD
Consultant Pathologist