

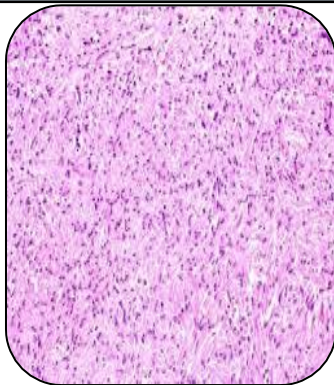
| | | | | | |
|---------------------|---------------|--------------------|-------------|--------------------------|------------|
| Patient Name | MR. DEEPAK | Client Name | Yadav Lab-B | Specimen Received | 23/11/2016 |
| Age/Sex | 20/M | Client Code | MOLQ1095CM | Specimen Type | Tissue |
| Patient ID | 011611230123 | Ref. Doctor | | Collection Date | 23/11/2016 |
| Specimen ID | MOLQ/B-769/16 | | | Report Date | 30/11/2016 |

SURGICAL PATHOLOGY REPORT

Benign Mesenchymal Lesion, Swelling scalp.

DIAGNOSIS

BENIGN MESENCHYMAL LESION.



SPECIMEN

Swelling scalp.

GROSS

i) Received 1x2.5cm greyish white cystic tissue piece.

Microscopy

- 1) Section examined shows Squamous lining epithelium.
- 2) Dermis shows large number of fibrocollagenous tissue, nerve bundles mononuclear inflammatory cells, blood vessels.
- 3) No granuloma and no malignant cells seen

Note : All biopsy specimen will be stored for 15 (fifteen)days, block and slides for 5(five) years only from the time of receipt at the laboratory. No request ,for any of the above ,will be entertained after the due date.

Reference

- i) Rosai and Ackerman's Surgical Pathology.
- ii) Modern Surgical Pathology.

Gulshan Yadav, MD
Consultant Pathologist