

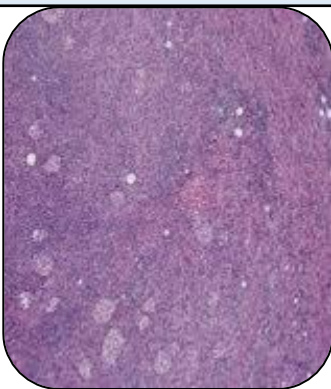
Patient Name	MR. KISHOR	Client Name	Satyam Hospital, MadanPuri	Specimen Received	20/11/2016
Age/Sex	36/M	Client Code	MOLQ1413CM	Specimen Type	Tissue
Patient ID	011611200051	Ref. Doctor		Collection Date	20/11/2016
Specimen ID	MOLQ/B-760/16			Report Date	26/11/2016

SURGICAL PATHOLOGY REPORT

Suggestive of Acute Appendicitis , Appendix.

DIAGNOSIS

SUGGESTIVE OF ACUTE APPENDICITIS.



SPECIMEN

Appendix.

GROSS

i) Received 6x1.5cm long appendix. Cut section shows fecolith.

Microscopy

- 1) Section examined shows lymphoid follicles with ulcerated mucosa.
- 2) Deeper tissue shows inflammatory infiltrate.

Note : All biopsy specimen will be stored for 15 (fifteen)days, block and slides for 5(five) years only from the time of receipt at the laboratory. No request ,for any of the above ,will be entertained after the due date.

Reference

- i) Rosai and Ackerman's Surgical Pathology.
- ii) Modern Surgical Pathology.

Gulshan Yadav, MD
Consultant Pathologist