

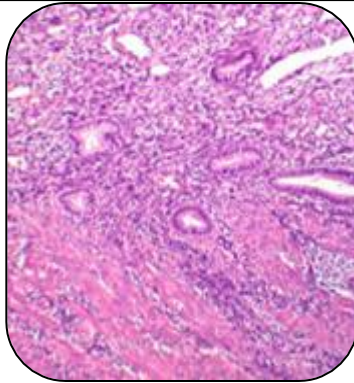
<b>Patient Name</b>	MRS. RABIYA SHALEYA	<b>Client Name</b>	Lifeaid Wellness Centre	<b>Specimen Received</b>	19/11/2016
<b>Age/Sex</b>	38/F	<b>Client Code</b>	MOLQ1476CM	<b>Specimen Type</b>	Tissue
<b>Patient ID</b>	011611190029	<b>Ref. Doctor</b>		<b>Collection Date</b>	19/11/2016
<b>Specimen ID</b>	MOLQ/B-756/16			<b>Report Date</b>	26/11/2016

## SURGICAL PATHOLOGY REPORT

### Endometrium Polyp.

#### DIAGNOSIS

**ENDOMETRIAL POLYP.**



#### SPECIMEN

Endometrium Polyp.

#### GROSS

i) Received multiple greyish white tissue pieces.

#### Microscopy

- 1) Section examined shows endometrium lining with small round to oval nucleus epithelial cells.
- 2) Small endometrial glands, cells having round nucleus.
- 3) Stroma shows predominantly mononuclear inflammatory cells infiltration.
- 4) No malignant cells seen and no granuloma seen.

**Note :** All biopsy specimen will be stored for 15 (fifteen) days, block and slides for 5 (five) years only from the time of receipt at the laboratory. No request, for any of the above, will be entertained after the due date.

#### Reference

- i) Rosai and Ackerman's Surgical Pathology.
- ii) Modern Surgical Pathology.

A handwritten signature in black ink, appearing to read 'Gulshan', written over a white rectangular background.

**Gulshan Yadav, MD**  
**Consultant Pathologist**

*Report generated at MolQ Laboratory, Gurgaon*