

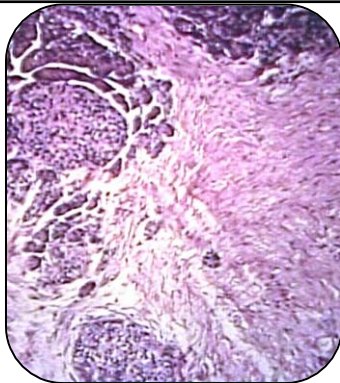
Patient Name	MRS. SEEMA	Client Name	Chetanya Hospital	Specimen Received	20/11/2016
Age/Sex	32/F	Client Code	MOLQ1255CM	Specimen Type	Tissue
Patient ID	011611200028	Ref. Doctor		Collection Date	20/11/2016
Specimen ID	MOLQ/B-759/16			Report Date	26/11/2016

SURGICAL PATHOLOGY REPORT

Proliferative Phase, Endometrium Biopsy (AUTOLYZED TISSUE).

DIAGNOSIS

PROLIFERATIVE PHASE.



SPECIMEN

Endometrium Biopsy (AUTOLYZED TISSUE)

GROSS

i) Received Autolyzed Blood.

Microscopy

- 1) Section examined shows small endometrial glands with autolytic changes in the cells and nucleus.
- 2) Stroma shows mononuclear inflammatory cells.
- 3) No malignant and no granuloma seen.

Note : All biopsy specimen will be stored for 15 (fifteen) days, block and slides for 5 (five) years only from the time of receipt at the laboratory. No request, for any of the above, will be entertained after the due date.

Reference

- i) Rosai and Ackerman's Surgical Pathology.
- ii) Modern Surgical Pathology.

A handwritten signature in black ink, appearing to read 'Gulshan', written over a white rectangular background.

Gulshan Yadav, MD
Consultant Pathologist