

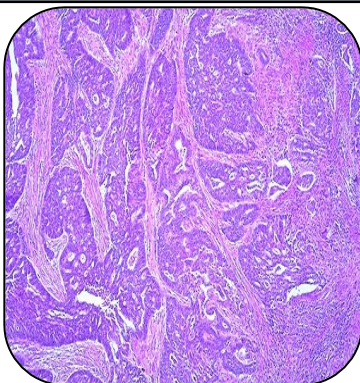
Patient Name	MRS. SURGAYAN	Client Name	Navastha Diagnostics	Specimen Received	18/11/2016
Age/Sex	30/F	Client Code	MOLQ1049P	Specimen Type	Tissue
Patient ID	011611180068	Ref. Doctor		Collection Date	18/11/2016
Specimen ID	MOLQ/B-754/16			Report Date	25/11/2016

SURGICAL PATHOLOGY REPORT

Normal Endometrium with Proliferative Phase, Endometrium Biopsy.

DIAGNOSIS

NORMAL ENDOMETRIUM WITH PROLIFERATIVE PHASE.



SPECIMEN

Endometrium Biopsy.

GROSS

i) Received multiple greyish white tissue pieces.

Microscopy

- 1) Section examined shows small endometrial glands having columnar epithelial cells with small round nucleus.
- 2) Stroma shows mononuclear cells and RBC.
- 3) No malignant cells and no granuloma seen

Note : All biopsy specimen will be stored for 15 (fifteen) days, block and slides for 5 (five) years only from the time of receipt at the laboratory. No request, for any of the above, will be entertained after the due date.

Reference

- i) Rosai and Ackerman's Surgical Pathology.
- ii) Modern Surgical Pathology.

Gulshan Yadav, MD
Consultant Pathologist