

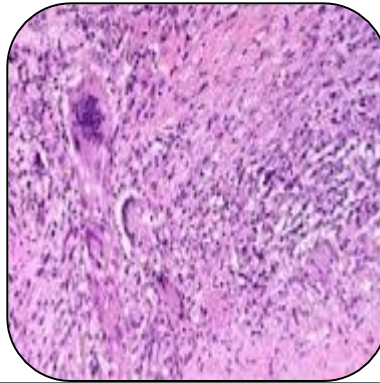
<b>Patient Name</b>	MRS. ZEENAT	<b>Client Name</b>	Pathdrug	<b>Specimen Received</b>	08/10/2016
<b>Age/Sex</b>	30/F	<b>Client Code</b>	MOLQ1234A	<b>Specimen Type</b>	Tissue
<b>Patient ID</b>	011610080025	<b>Ref. Doctor</b>	DR. Shradha Maheshwari	<b>Collection Date</b>	08/10/2016
<b>Specimen ID</b>	MOLQ/B-669/16			<b>Report Date</b>	14/10/2016

## SURGICAL PATHOLOGY REPORT

**Infective lesion, Abscess wall tissue.**

### DIAGNOSIS

**INFECTIVE LESION.**



### SPECIMEN

Abscess wall tissue.

### GROSS

Received 2x3cm multiple greyish white tissue pieces.

### Microscopy

- i) Section examined shows fibrocollagenous tissue mature adipose cells with inflammatory cells (lymphocytes, eosinophils and plasma cells).
- ii) Section also shows few small blood vessels and ducts.
- iii) No granuloma and no malignant cells.

### Reference

- i) Rosai and Ackerman's Surgical Pathology.
- ii) Modern Surgical Pathology.

**Gulshan Yadav, MD**  
**Consultant Pathologist**