

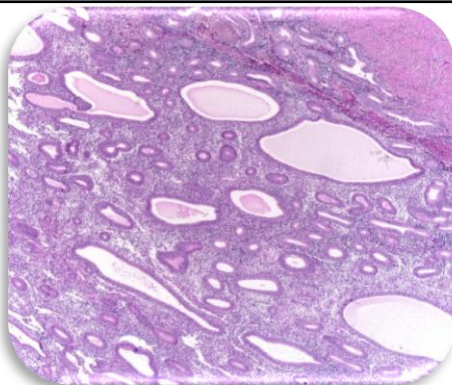
<b>Patient Name</b>	MRS. GEETA	<b>Client Name</b>	Patient Care Centre	<b>Specimen Received</b>	01/10/2016
<b>Age/Sex</b>	35/F	<b>Client Code</b>	MolQ1249CM	<b>Specimen Type</b>	Endometrial
<b>Patient ID</b>	011610010164	<b>Ref. Doctor</b>	Dr. SUMEDHA HARNAE	<b>Collection Date</b>	01/10/2016
<b>Specimen ID</b>	MOLQ/B-659/16			<b>Report Date</b>	07/10/2016

## SURGICAL PATHOLOGY REPORT

**Simple hyperplasia without atypia.**

### DIAGNOSIS

**SIMPLE HYPERPLASIA.**



### SPECIMEN

Endometrial.

### GROSS

i) Received 0.1x6 cm tiny tubular tissue piece.

### Microscopy

- i) Section examined shows small endometrial glands.
- ii) Stroma shows mononuclear inflammatory cells.
- iii) Few glands are cystically dilated.

**Note :** All biopsy specimen will be stored for 15 (fifteen) days, block and slides for 5 (five) years only from the time of receipt at the laboratory. No request, for any of the above, will be entertained after the due date.

### Reference

- i) Rosai and Ackerman's Surgical Pathology.
- ii) Modern Surgical Pathology.

**Gulshan Yadav, MD**  
Consultant Pathologist

Report generated at MolQ Laboratory, Gurgaon