

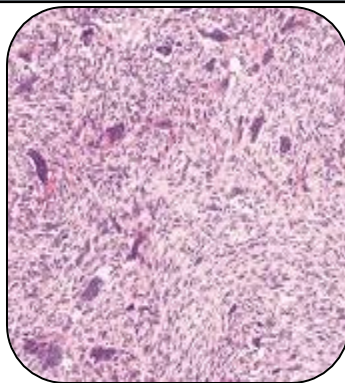
Patient Name	MS. TANYA GUPTA	Client Name	Pathdrug	Specimen Received	06/05/2016
Age/Sex	17/F	Client Code	MOLQ1234A	Specimen Type	Tissue
Patient ID	011605060020	Ref. Doctor	DR. D. K. Gupta	Collection Date	06/05/2016
Specimen ID	MOLQ/B-252/16			Report Date	12/05/2016

SURGICAL PATHOLOGY REPORT

Benign mesenchymal lesion, Swelling right 3rd toe.

DIAGNOSIS

BENIGN MESENCHYMAL LESION.



SPECIMEN

Swelling right 3rd toe.

GROSS

Received 1x2cm greyish white tissue piece.

Microscopy

- i) Section examined shows fibrocollagenous tissue, small blood vessels and inflammatory cells.
- ii) Section also shows nerve bundles.
- iii) No granuloma and no malignant cell seen.

Reference

- i) Rosai and Ackerman's Surgical Pathology.
- ii) Modern Surgical Pathology.

Gulshan Yadav, MD
Consultant Pathologist