

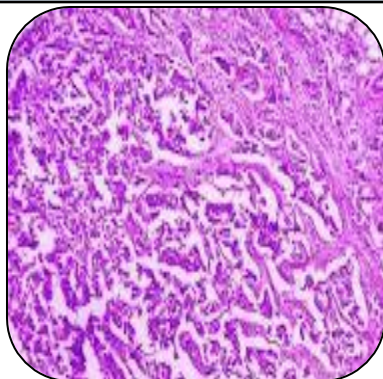
Patient Name	MRS. KANTA	Client Name	Aryan Hospital	Specimen Received	11/03/2016
Age/Sex	40/F	Client Code	MOLQ1305CM	Specimen Type	Tissue
Patient ID	011603120192	Ref. Doctor		Collection Date	11/03/2016
Specimen ID	MOLQ/B-120/16			Report Date	21/03/2016

SURGICAL PATHOLOGY REPORT

Fibrocytic disease of left breast, Left Breast Cyst.

DIAGNOSIS

FIBROCYSTIC DISEASE OF LEFT BREAST.



SPECIMEN

Left Breast Cyst.

GROSS

Received 2x2cm greyish white tissue piece.

Microscopy

- i) Section examined shows dilated ducts surrounded by fibrocollagenous tissue and small blood vessels.
- ii) Ductal cells shows round to oval nucleus with epithelial cell.
- iii) No granuloma and no malignant cell seen.

ADVICE

Kindly correlate clinically.

Reference

- i) Rosai and Ackerman's Surgical Pathology.
- ii) Modern Surgical Pathology.

Gulshan Yadav, MD
Consultant Pathologist