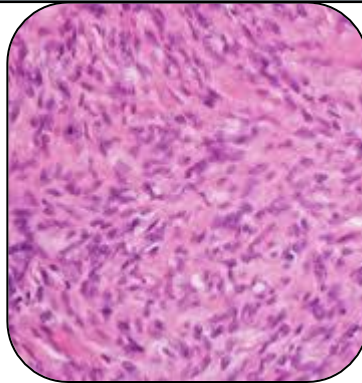


Patient Name	MRS. MITHLESH	Client Name	MolQ Collection Centre	Specimen Received	11/03/2016
Age/Sex	52/F		NRR	Specimen Type	TISSUE
Patient ID	021603110001	Client Code	MOLQ1251CC	Collection Date	11/03/2016
Specimen ID	MOLQ/B-115/16	Ref. Doctor	Dr. DIPIKA DHINGRA	Report Date	17/03/2016

SURGICAL PATHOLOGY REPORT
Endocervical polyp with chronic cervicitis, Endocervical polyp
and Endocervical curettage

DIAGNOSIS

ENDOCERVICAL POLYP WITH CHRONIC CERVICITIS.



SPECIMEN

- I) Endocervical polyp
- II) Endocervical curettage

GROSS

- I) Received 1x1cm greyish white tissue piece.
- II) Received multiple greyish white tissue pieces.

MICROSCOPIC DIAGNOSIS

- I) **Endocervical polyp:**
Section examined shows squamous epithelial lining with nabothian cyst and inflammatory infiltrate. No granuloma and no malignant cell seen.
- II) **Endocervical curettage:**
Section examined shows endocervical glands and blood clot.

Reference

- i) Rosai and Ackerman's Surgical Pathology.
- ii) Modern Surgical Pathology.

Gulshan Yadav, MD
Consultant Pathologist