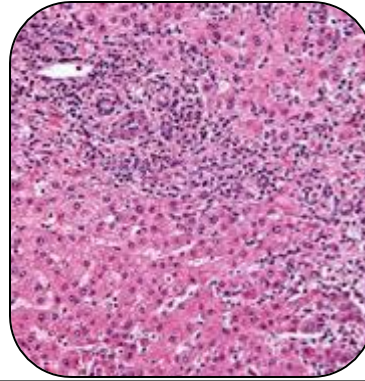


<b>Patient Name</b>	MRS. CHANDAN	<b>Client Name</b>	Cheeka MoIQ Health Services	<b>Specimen Received</b>	28/01/2016
<b>Age/Sex</b>	32/F	<b>Client Code</b>	MOLQ1203P	<b>Specimen Type</b>	Tissue
<b>Patient ID</b>	011601280024	<b>Ref. Doctor</b>	DR. NIDHI BANSAL	<b>Collection Date</b>	28/01/2016
<b>Specimen ID</b>	MOLQ/B-39/16			<b>Report Date</b>	30/01/2016

## SURGICAL PATHOLOGY REPORT

### Uterus with cervix.

#### DIAGNOSIS



#### SPECIMEN

Uterus with cervix.

#### GROSS

- i) Received 11x6cm long Uterus with cervix (hypertrophy) with bilateral ovary.
- ii) One ovary 3x3cm and another 3x2cm.
- iii) One ovary shows small cyst with blood clot.

#### Microscopy

- i) Endometrium - Proliferative Phase.
- ii) Myometrium - Unremarkable.
- iii) Cervix – Chronic Cervicitis.
- iv) Bilateral Tubes and Ovary - Tubes Unremarkable. One ovary shows luteal cyst and another shows hemorrhagic cyst.

#### Reference

- i) Rosai and Ackerman's Surgical Pathology.
- ii) Modern Surgical Pathology.

**Gulshan Yadav, MD**  
**Consultant Pathologist**